

# The role of colposcopy in cervical precancer

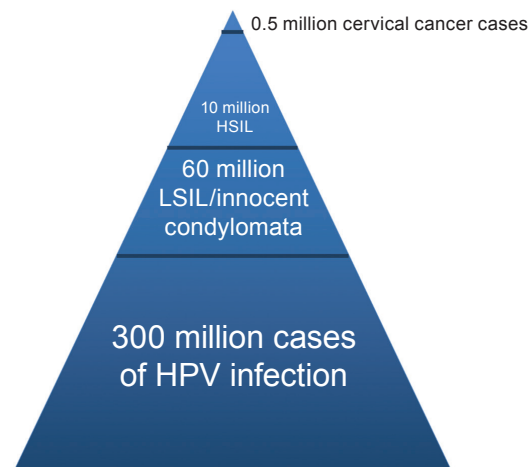
A positive *diagnostic* test result reveals an abnormality or disease. Advice about management is usually accepted willingly. When a woman receives an abnormal cervical screening test result, the expectations and fears that she carries are quite different. Cervical *screening* tests – whether visual inspection, cervical cytology, or human papillomavirus (HPV) tests – do not give a diagnosis; rather, they modify the risk for an individual of developing cervical cancer. The progression to precancer and cancer is slow and is a very uncommon outcome for screen-positive women (Fig. 1.1).

The threshold of abnormality at which the risk of cancer outweighs any disadvantage of treatment varies according to patient characteristics and local service considerations. The World Health Organization (WHO) advises treatment at the high-grade

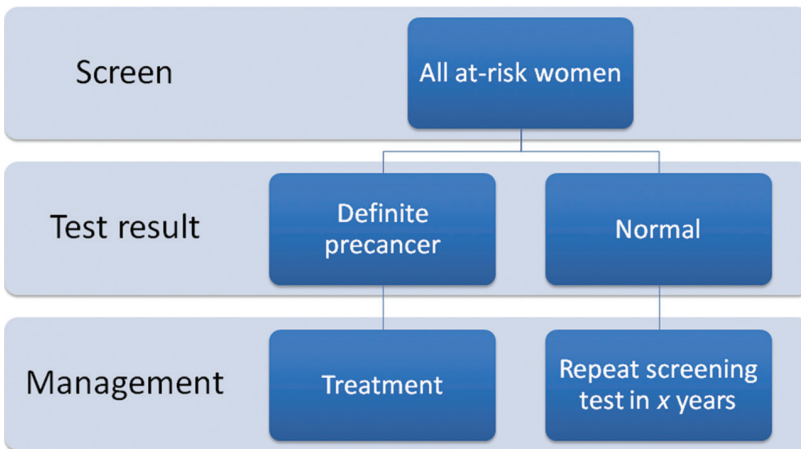
squamous intraepithelial lesion (HSIL) level (cervical intraepithelial neoplasia grade 2 [CIN2] or greater). However, in many countries with established screening programmes

and where low rates of default from follow-up exist, the threshold for treatment may be higher, especially in young women. The management of screen-positive women would

**Fig. 1.1.** Relative rates of human papillomavirus (HPV) infection, low-grade squamous intraepithelial lesion (LSIL), and cervical cancer (high-grade squamous intraepithelial lesion [HSIL]).



**Fig. 1.2.** The ideal, dichotomous screening test.



be much easier if the results of screening tests were diagnostic and dichotomous. An ideal screening test would provide two possible answers, and management advice would be simple (Fig. 1.2).

But current screening tests for cervical precancer are neither completely sensitive nor absolutely specific. For example, testing for oncogenic (or high-risk) HPV will pick up almost all cervical precancerous lesions but will also test positive in women who have innocent and transient high-risk HPV infection. In a recent study, 73% of women with a positive oncogenic HPV test also had a negative or normal smear (Kati et al., 2011). Cytology, in contrast, is far more specific than HPV testing but will miss a number of women in

whom there is a risk of precancer. Because of this, cytology testing has to be performed relatively frequently (3–5-yearly). The long natural history of cervical cancer is forgiving of the relatively poor sensitivity of cytology.

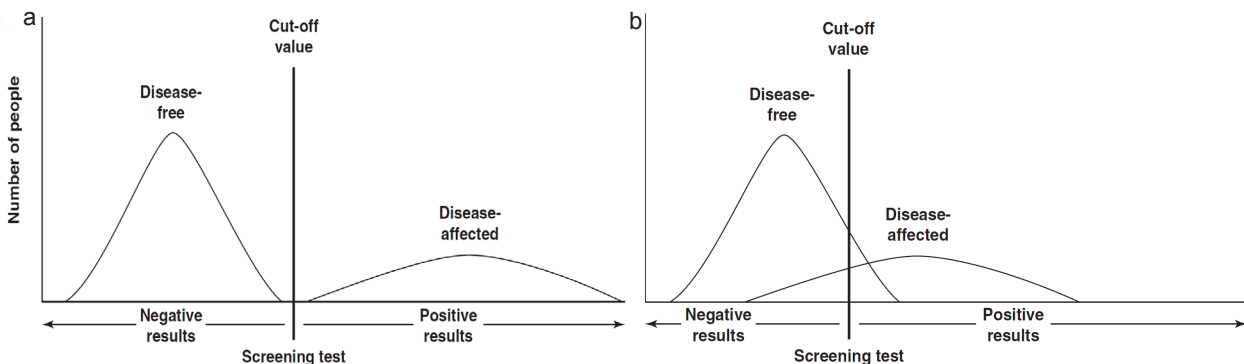
Also, cytology will sometimes recognize cells that are very mildly abnormal, or even of a “borderline” nature: borderline nuclear abnormality, and atypical squamous cells of undetermined significance (ASCUS). These categories of abnormality create headaches and frustration for both clinician and patient. They include mostly women who are not at a high risk of progression, as well as a minority of women who are. Clearly, the ideal test – not yet available – would identify only the women who are at a high risk of progression to

cancer. The problem of imperfect sensitivity and specificity is illustrated in Fig. 1.3.

Visual inspection with acetic acid (VIA) is fast becoming the de facto screening method of choice in many regions where cytology and HPV testing are out of reach. A “screen-and-treat” approach is gaining popularity as an efficient method of reaching large numbers of women in difficult circumstances. However, the specificity of VIA is poor, and the difficulty of missing endocervical lesions (whether they are squamous or glandular) is a real problem. Over-treatment of women with false-positive VIA test results is perceived as a necessary trade-off to reduce the overall incidence of cervical cancer.

Thus, screening tests (VIA, cytology, and HPV testing) are imperfect, and women with an abnormal primary screening test need further consideration before reflex referral to colposcopy and/or management. For those women in whom a suspicion of CIN2 has been reported, referral to colposcopy is still the appropriate advice. (When considering treatment, lesser grades of abnormality, or CIN2 with negative p16, the cost-benefit equation is less certain.) The concept of triage is to use other tests for women who have an imprecise primary screening test report, so that those women who have a genuine risk of progression to cancer

**Fig. 1.3.** (a) The ideal screening test. (b) The real screening test.



may be identified and referred for colposcopy and management. Also, just as importantly, women who are at a very low risk of progression may be spared the interventions of biopsy and/or treatment. Colposcopy is also important in avoiding overtreatment that may occur with “screen-and-treat” programmes where false-positive rates may be very high (Basu et al., 2015). Finally, colposcopy may recognize invasive cancer not heralded by a screening test.

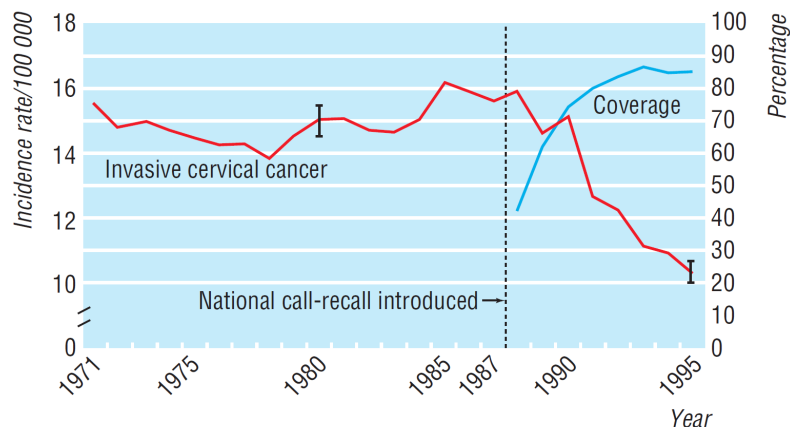
### 1.1 Traditional screening: rationale and practice

Systematic high-coverage and quality-assured population screening and treatment for precursors to cervical cancer are highly effective. The conditions for an ideal screening test as enunciated by Wilson and Jungner (1968) apply very precisely to cervical cancer. The disease has a long precancerous phase, effective screening tests are available and are easily performed, and the disease is common enough to justify the expense of population screening, even in low- and middle-income countries (LMICs) (Denny and Prendiville, 2015). Finally, there are effective and low-morbidity preventive treatments of proven value for screen-positive women. In those countries and regions that have implemented quality-assured, high-coverage call-and-recall screening programmes for cervical precancer, large reductions have been demonstrated in the rates of both incidence of and mortality from cervical cancer (Figs. 1.4 and 1.5).

### 1.2 Management of screen-positive women

In the traditional system, a cervical smear test is the usual screening tool (Fig. 1.6). The microscopic examination of cellular material to

**Fig. 1.4.** Age-standardized incidence of invasive cervical cancer and coverage of screening in England, showing a decrease in incidence after the introduction of a national call-and-recall screening programme.



recognize morphological changes allows cytologists to report different degrees of abnormality, classified as borderline, low-grade, or high-grade in squamous or glandular cells. High-grade smear abnormalities are associated with a higher risk of cervical cancer development over the subsequent decade, and low-grade and borderline smears are associated with a dramatically lower risk.

Of course, it is not the screening itself that prevents cervical

cancer, but rather the subsequent management of screen-positive women. Screen-positive women may be stratified according to risk and either referred to a colposcopist or retested some time later. Classically, colposcopic examination facilitates the recognition and localization of genuinely high-grade abnormality within the “at-risk” epithelium – i.e. the transformation zone (TZ) – and facilitates either confirmatory biopsy or excision/ablation of the TZ, or both.

**Fig. 1.5.** Projected cervical cancer deaths without any screening (England and Wales). Dashed line represents cervical cancer deaths that would have happened after 1987 without screening. Solid line shows annual deaths from 1953 to 2002. Arrow indicates start of national screening in 1988.

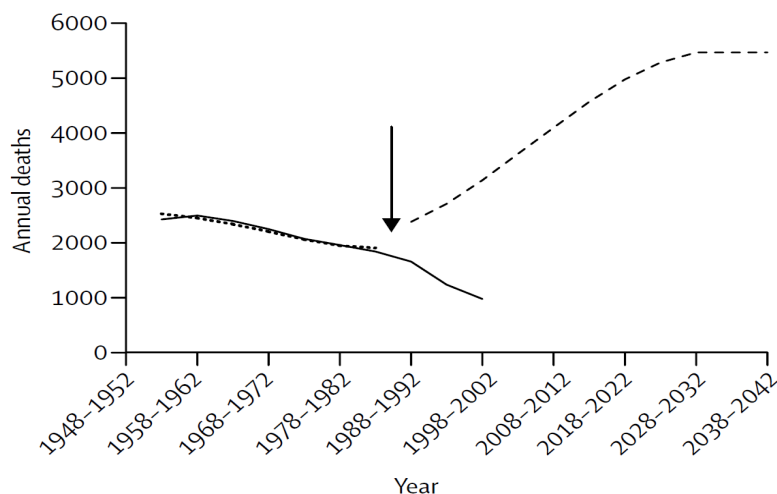
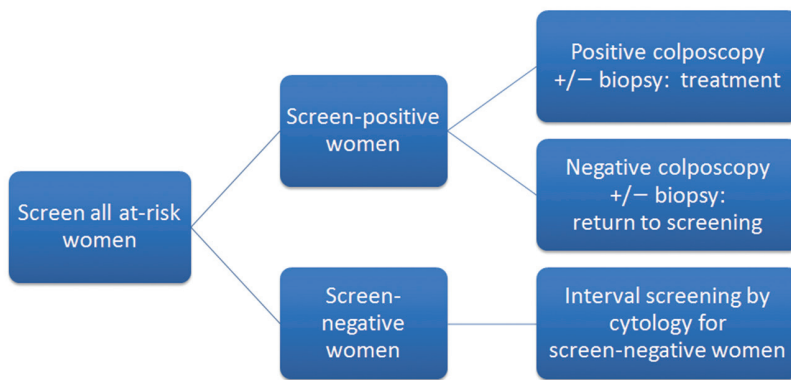


Fig. 1.6. Traditional algorithm for screen-positive cases.



Established treatment modalities are effective. Through well-organized screening programmes and the management of screen-positive women, incidence and mortality rates have been reduced significantly (Arbyn et al., 2009; IARC, 2005; Miller, 1993; Peto et al., 2004; Sasieni et al., 2003). For many years, this system or model of *screen, colposcope, and treat selected patients* has been standard and highly successful.

But the protocol is not perfect. It was a practical and workable system 30 years ago. For example, in the United Kingdom, women were not, at that time, referred for colposcopic examination unless the cytologist considered there to be a significant risk of progression to cancer – in other words, when there was a smear report describing changes suggesting severe dysplasia (i.e. a smear report of severe dyskaryosis). At that time, women with minor abnormalities were followed up with repeat cytology. The threshold for referral to colposcopy was relatively high, and most women who were referred had a high-grade smear report that was usually confirmed and managed at colposcopy. The decision to proceed to treatment was uncomplicated and had consensus support. Also in the 1980s, large loop excision of the transformation zone (LLETZ), which later became known as loop

electrosurgical excision procedure (LEEP) in the USA, was introduced as a simple excisional outpatient treatment (Prendiville et al., 1989). This technique largely replaced laser treatment and other destructive methods because of its simplicity, cost-effectiveness, and facility for comprehensive histological assessment of the removed TZ. In selected cases it obviated the need for a preliminary colposcopically directed biopsy.

Although it has been known for some time that low-grade abnormalities have a low risk of progression (Moscicki et al., 2010), it became clear that some cytological low-grade or borderline smears harbour higher-grade lesions. As a result, women with minor-grade abnormalities were increasingly referred for immediate colposcopic evaluation, and in time the majority of women with an abnormal smear of almost any grade were, in some regions, referred for colposcopic examination. In some parts of Europe and the USA, where screening was routinely offered annually and often to very young women, the risk of unnecessary treatment became commonplace.

During the 1980s and 1990s, the number of women referred for colposcopic examination increased exponentially. To add fuel to the fire of overtreatment, the ease with which

routine office or outpatient LLETZ could be learned and performed, compared with laser treatment or cold-knife cone biopsy, meant that the threshold for treatment fell. At about the same time, reporting rates for low-grade and borderline abnormalities varied enormously. In Ireland's National Cancer Screening Service, for example, at the beginning of its cervical screening programme all smears were sent to a laboratory in the USA. Of these specimens, 14.9% were reported as "not normal", rates similar to those for VIA. Finally, as the very high sensitivity of oncogenic HPV testing became apparent, the test became used widely, either on its own or in combination with cytology. The management of screen-positive women became more complex. The optimal "next step" for most women with any "not normal" smear is no longer automatic referral for colposcopy and treatment.

### 1.3 Clinical guidelines

Against this background, some national societies of colposcopy and cervical pathology have taken on the responsibility of generating clinical guidelines for physicians and colposcopists as an aid to management.

For example, in the United Kingdom, the National Health Service (NHS) Cervical Screening Programme produced a clinical guidelines document entitled *Colposcopy and Programme Management: Guidelines for the NHS Cervical Screening Programme* (NHS, 2004), which encompassed screening, management, and follow-up guidelines for clinicians involved in the United Kingdom screening programme. It was updated in 2010 and 2016 (NHS, 2010, 2016) and is a valuable reference document for anyone involved in cervical precancer screening and/or management.



In 2001, a new reporting system for cytology smears was published in the USA, and at about the same time the results were published of a large study in the USA reporting different strategies for managing minor cytological abnormalities (ASCUS-LSIL Triage Study (ALTS) Group, 2003a, 2003b). To guide physicians in the USA, the American Society for Colposcopy and Cervical Pathology (ASCCP) implemented a process that developed broad consensus guidelines to aid clinicians in managing women with abnormal cervical cytology. These guidelines became a defensible and practical aid for a busy gynaecologist to use in everyday practice in the USA (Massad et al., 2013; Nayar and Wilbur, 2015; Wright et al., 2003), and they apply to the context of screening principle and practice in the USA. This is not meant to be a criticism of the process but should make the reader wary about using management algorithms outside of the context in which they were generated.

#### 1.4 Risk assessment in patient management

When to advise the asymptomatic screen-positive woman to have further intervention requires an assessment of risk. Does the risk of intervention outweigh the risk of cancer evolving? Many of the triage recommendations contained in management algorithms depend exclusively on the result of the screening test. For example, it may advise an oncogenic HPV test for a woman with a smear report of ASCUS. But there are other factors that modify the relative risk of progression (Mergui et al., 2010). A smear reporting *HSIL-moderate dyskaryosis* carries a very different risk of progression to cancer in a woman younger than 30 years compared with a woman older than 40 years. Age, smoking, and other

influences modify the risk equation. Finally, the likelihood of default from follow-up monitoring of untreated patients needs to be taken into consideration. This thinking was developed in a clinical opinion paper in 2007 (Castle et al., 2007). The paper put forward cogent arguments for using a quantifiable risk assessment rather than an individual test result as the arbiter of management. It extended the principle beyond cytology to colposcopy and histology (Fig. 1.7).

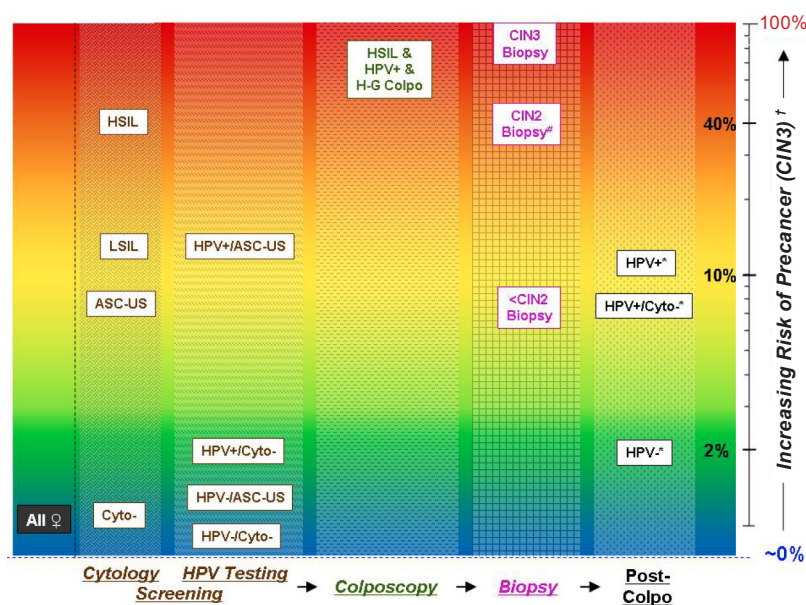
When assessing the threshold for referral to colposcopy or for treatment, some researchers have defined thresholds of risk. The 2012 ASCCP clinical guidelines document (Massad et al., 2013) includes a risk of progression (Table 1.1) that reflects this approach.

#### 1.5 Screening and triage options in current practice

There are several different scenarios where triage might be useful in the management of cervical precancer. Local circumstances, cost, availability of test facilities, and expertise will all play a role in determining which primary screening tool is used and which secondary or triage test is used. Examples are illustrated in Figs. 1.8–1.11.

Primary screening tests may also be used as triage tools (cytology, HPV testing, or VIA), and some are used in conjunction with others to improve the test characteristics of the primary screening test (co-testing with cytology and HPV; dual testing, i.e. p16/Ki-67, with HPV). Finally,

**Fig. 1.7.** Graphical representation of the risk of cervical precancer at different stages and results of screening and clinical management for cervical cancer prevention. The risks for each stage and result are approximate risks for cervical intraepithelial neoplasia grade 3 (CIN3) within a screening interval. The axis to the right of the figure represents increasing risk, from nearly 0% (blue) to 100% (red), of cervical precancer on a logarithmic scale. Each stage of screening and clinical management is represented by a different pattern, and the arrows at the bottom indicate the sequence of the stages. # Less than half of the cases of CIN2 on biopsy are subsequently diagnosed as CIN3 on excisional tissue (precancer). † Within a screening interval. \* Test results at the next follow-up visit ( $\geq 6$  months).

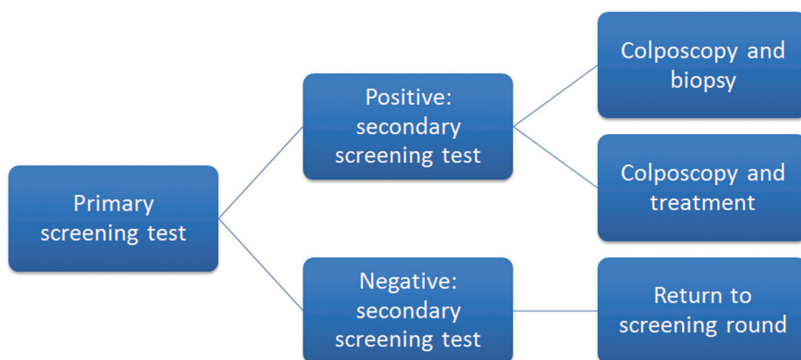


**Table 1.1.** Referral or follow-up according to risk of CIN3

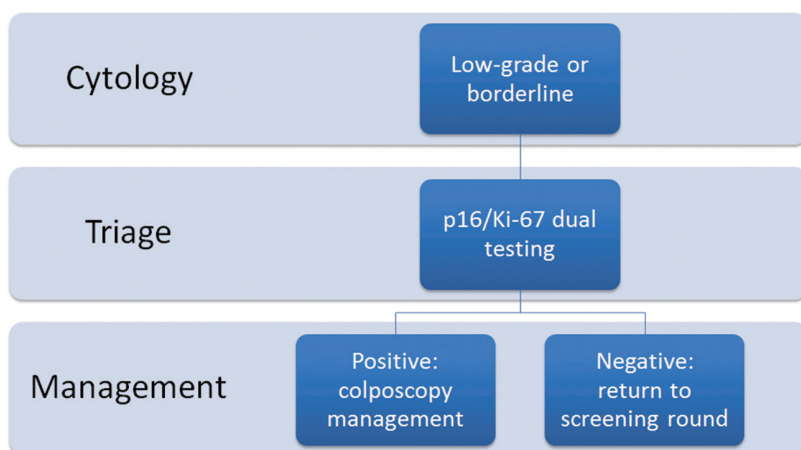
Risk of CIN3	Recommended action
> 5%	Immediate referral for colposcopy
2–5%	6–12-month follow-up
0.1–2%	3-year follow-up
< 0.1%	5-year follow-up

CIN3, cervical intraepithelial neoplasia grade 3.

**Fig. 1.8.** Generic use of triage after primary screening.



**Fig. 1.9.** Possible triage of low-grade and borderline smears using p16/Ki-67 dual testing.



repeat cytology has also been used as a triage tool for minor-grade cytology reports.

### 1.5.1 VIA and VILI

Two naked-eye inspection methods are in widespread use in LMICs: VIA and visual inspection with Lugol's

iodine (VILI). They may be performed by nurses or other primary health-care workers. They use light-illuminated speculum examination of the cervix after the application of 5% acetic acid (VIA) or Lugol's iodine (VILI).

VIA and VILI are inexpensive and simple, and can be carried out

by primary care staff trained in a relatively short time. Visual inspection provides an immediate result that can be determined on-site in hospitals, in clinics, or in the field and allows the health-care worker the opportunity to immediately treat those TZs that are possibly abnormal. The sensitivity and the specificity of visual inspection techniques are highly variable and are very reliant on quality-assured training and retraining (Sankaranarayanan et al., 2007; Sauvaget et al., 2011). Of course, these methods only assess the ectocervix and will miss endocervical lesions, with consequent poorer performance in older women. Finally, visual inspection is very unlikely to detect glandular intraepithelial lesions or squamous lesions in the canal (some type 2 TZs and most type 3 TZs).

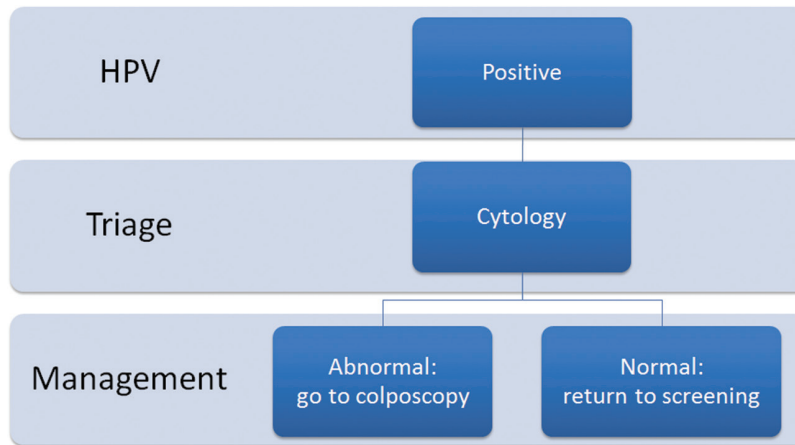
#### 1.5.1.1 Digital VIA

Given the concerns about suboptimal sensitivity and lack of an efficient quality assurance mechanism for VIA-based screening, modifications of the method have been used in some regions. For example, Parham et al. (2015) have used enhanced magnification of cervical lesions, peer review, quality assurance, continuing medical education, objective recording of screening test results, and access to expert opinion in their screen-and-treat programme in Zambia. Treatment decisions are made primarily on the basis of VIA. However, if there are disagreements between VIA and enhanced magnified images, then the images are used to make the final decision.

### 1.5.2 Cytology

Cervical cytology smears need to be examined by properly trained and quality-assured cytologists. The subsequent treatment of women

**Fig. 1.10.** Possible triage of positive HPV test using cytology.



with high-grade CIN prevents the development of cancer (Miller, 1993). However, in LMICs, cytology has not been as successful, for several reasons. Unless strict and continuing quality control programmes are in place, cytology may perform poorly in terms of recognizing abnormal lesions. It has good specificity but lacks sensitivity, and in some series may be associated with sensitivity rates of only 50% (Arbyn et al., 2009; Nanda et al., 2000). Also, the test requirements are expensive, and the screening interval needs to be relatively frequent (3–5 years). Finally, in many regions the facilities necessary

to collect, process, and report cytology are simply not available. It is highly unlikely that health systems in LMICs will wish to establish cytology as the primary screening tool for cervical cancer prevention.

### 1.5.3 HPV testing

HPV DNA testing will probably replace or complement cytology as the primary screening tool in many developed countries for women older than 30 years (Arbyn et al., 2013). Because of the absolute relationship between oncogenic HPV infection and cervical cancer, the negative

predictive value of HPV testing is very high. A large number of studies have investigated how best to use this information. HPV testing for all known oncogenic types has been available and approved for many years.

There are essentially three realms where oncogenic HPV testing is of proven clinical utility:

- as a screening tool in women older than 30 years;
- as a triage tool for women with low-grade cytological abnormalities; and
- as a follow-up tool for women who have been treated for squamous or glandular cervical precancer.

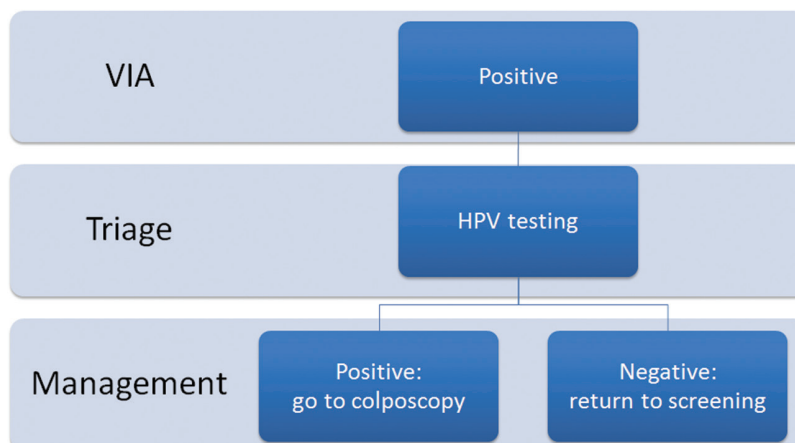
#### 1.5.3.1 Oncogenic HPV testing as the primary screening tool

Sankaranarayanan et al. (2009) first demonstrated in a large cluster randomized controlled trial (RCT) that a single round of HPV testing was superior to cytology or VIA or no screening in reducing the incidence of advanced cervical cancer and in reducing mortality from cervical cancer.

Four RCTs of HPV screening versus routine cytological screening have been undertaken in Europe. In these studies together, 176 464 women aged 20–64 years were randomly assigned to HPV-based (experimental arm) or cytology-based (control arm) screening in England, Italy, the Netherlands, and Sweden.

In all four studies, the incidence of CIN3 was lower in those women who had initially been screened by HPV than in those initially screened by cytology, and similar rates of reduction were recorded in each study. This reduced rate was true across all studies despite differences in screening protocols between the studies. Because none of the individual studies was sufficiently large to show a reduction in cancer

**Fig. 1.11.** Possible use of HPV testing for triage of positive visual inspection with acetic acid (VIA) test.



incidence, a recent overview of the pooled data has been undertaken by Ronco et al. (2014).

The 176 464 women were followed up for at least two rounds of cervical screening, equating to a median of 6.5 years. A total of 107 invasive cervical carcinomas were found. The authors concluded in their summary: “HPV-based screening provides 60–70% greater protection against invasive cervical carcinomas compared with cytology. Data of large-scale randomised trials support initiation of HPV-based screening from age 30 years and extension of screening intervals to at least 5 years.” The results of this overview are very convincing.

### *1.5.3.2 Oncogenic HPV testing as a triage tool for women with low-grade cytological abnormalities*

As the threshold for referral for investigation of smear abnormalities fell over the past two decades, the number of women attending colposcopy increased. As a general principle, women with any degree of cytological abnormality require either follow-up or treatment, depending on the risk of progression to cancer. There is consensus that most women with high-grade lesions should be referred for colposcopy and managed according to colposcopic assessment and/or biopsy results. However, for low-grade abnormalities, no such consensus exists (Cox, 2005; Sawaya, 2005; Soutter, 1994). The reason is that it is not possible to predict the natural history of minor-grade lesions on the basis of cytology alone. Low-grade abnormalities often regress (Melnikow et al., 1998; Ostör, 1993), and the potential for overtreatment is obvious. However, some studies reported relatively high rates of high-grade or moderate-grade abnormalities in women

with low-grade cytology reports, even as high as 30% (Kinney et al., 1998). The search has continued for a triage tool to discriminate women at genuine risk of having or developing CIN3.

However, the management of women with minor-grade lesions remains controversial, and follow-up recommendations for women with ASCUS and low-grade squamous intraepithelial lesion (LSIL) have varied from conservative management (i.e. repeat cytology) to immediate referral for colposcopy and biopsy (Soutter et al., 2004). Because of the crucial role that HPV infection plays in the genesis of cervical cancer, HPV testing has been investigated as an alternative to repeat cytological testing, in a large number of disparate studies. Several formal reviews of these studies have been performed. The most recent Cochrane review (Arbyn et al., 2013) advised that for triage of women with LSIL, the Hybrid Capture 2 (HC2) oncogenic HPV test yields a significantly higher sensitivity, but a significantly lower specificity, compared with repeat cytology.

### *1.5.3.3 Oncogenic HPV testing as a follow-up tool for women who have been treated for squamous or glandular cervical precancer*

Because residual disease and recurrent disease can occur up to 20 years after treatment, it is important to implement a follow-up protocol wherever possible (Soutter et al., 2006). A number of RCTs and several meta-analyses have demonstrated that HPV testing is the best *test of cure* (Arbyn et al., 2005). It has replaced cytology and colposcopy in several national clinical guidelines documents, although many still advise co-testing with cytology. Finally, several reviews have concluded that

HPV testing is more cost-effective than cytology in the context of a European national screening programme (Coupé et al., 2007; Legood et al., 2012).

## **1.6 Colposcopy**

### *1.6.1 What is colposcopy?*

Colposcopy is low-powered microscopic and light-illuminated examination of the lower genital tract epithelium. The first reported use of a colposcope was in Hamburg, Germany, in the early 1920s as a result of a collaboration between the University of Hamburg and the German microscope manufacturer Leitz.

The early work published in the 1930s from Hamburg described the origins of cervical cancer being in a sheet of epithelium, i.e. intraepithelial, as opposed to arising from a single focal lesion. During the 1930s and 1940s, colposcopy practice spread and evolved throughout Europe. It was not until the 1960s and 1970s that colposcopy became more widely established, through individual experts.

### *1.6.2 What can colposcopy be used for?*

Colposcopy may be used to examine any epithelial surface of the lower genital tract. Some of the indications for colposcopy are given in Table 1.2. It may be used as a primary screening tool and as a way of facilitating different treatment modalities. Colposcopy does not perform well as a primary screening tool (Leeson et al., 2014). It is also used to examine the vulva, the anus, the vagina, and more recently the oropharynx as well as the penile epithelium, because each of these sites is prone to developing colposcopically recognizable precancerous lesions. Colposcopy has also been used in



**Table 1.2. Common indications for colposcopy**

What is colposcopy best used for?
• A suspicious-looking cervix
• Symptoms suggestive of cervical cancer, e.g. persistent postcoital bleeding, persistent intermenstrual bleeding
• Cervical leukoplakia
• A cytological abnormality
• A positive VIA or VILI screening test
• A positive high-risk HPV test in the presence of a low-grade or borderline smear abnormality or other screening test abnormality

HPV, human papillomavirus; VIA, visual inspection with acetic acid; VILI, visual inspection with Lugol's iodine.

clinics investigating lower genital tract infection. However, the great majority of colposcopic examinations are of the cervix with suspected precancer.

The performance of colposcopy as a purely diagnostic tool is known to be influenced by the result of the screening test, and there are several studies where colposcopy has not performed well (Jeronimo and Schiffman, 2006; Pretorius et al., 2011). However, in those countries where colposcopy is part of a properly constructed, quality-assured programme, it is associated with a very high negative predictive value (Cruickshank et al., 2015; Kelly et al., 2012; Ricci et al., 2015). Also, colposcopy is not just a diagnostic tool; indeed, that is not even its most valuable role.

***The colposcopic examination should undertake and document the following:***

1. Assess the state of the cervix at the time of examination, and determine whether it is possible to undertake an adequate examination (see Chapter 6).
  - a. Assess the hormonal status.
    - i. Is the epithelium well-estrogenized?
    - ii. Are pregnancy changes present?
    - iii. In postmenopausal women, is the degree of atrophic epithelial change sufficient to consider prescribing topical estro-

gen before colposcopic assessment?

- b. Determine whether there is inflammation.
    - i. Is infection (viral, fungal, bacterial) present, and is investigation and treatment prudent before colposcopic assessment?
  - c. Confirm full visibility of the entire cervix and upper vagina under colposcopic view.
  - d. Determine whether there is evidence of previous treatment, or any degree of epithelial fibrosis.
- Once these assessments have been made, it will be possible to determine whether a complete colposcopic examination can be undertaken. If so, the following steps should be performed.
2. Determine the type and size of the TZ:
    - a. TZ type (see nomenclature in Chapter 7, and Annex 1)
    - b. TZ size (small or large).
  3. Recognize epithelial abnormality (i.e. is disease present?).
    - a. Cervical precancer non-invasive or intraepithelial abnormality classified as:
      - i. CIN1 or LSIL
      - ii. CIN2 or HSIL-CIN2
      - iii. CIN3 or HSIL-CIN3.
  4. Document the above examination findings in a standard and auditable format (see Annex 2) using the most recent International

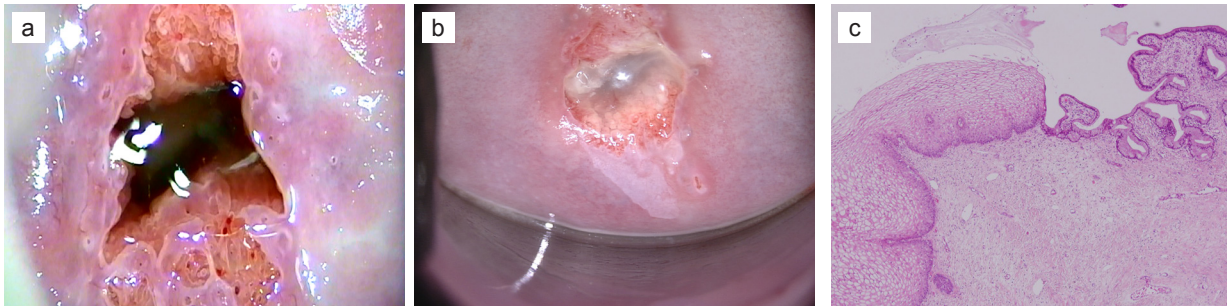Federation of Cervical Pathology and Colposcopy (IFCPC) nomenclature or terminology (see Annex 3).

5. Compile a Swede score (see Annex 4).
6. Where possible, take a video or a number of pictures of the examination findings so as to record:
  - a. the TZ type and size
  - b. the site(s) of greatest abnormality
  - c. the site of any biopsy
  - d. the treatment, if performed.

Misunderstanding the role of the colposcopic examination is common, to the extent that some authors consider the major role of colposcopy to be guiding the diagnostic biopsy (Jeronimo and Schiffman, 2006; Wentzensen et al., 2015). Some aspects of colposcopic evaluation are contextual, and some are not. Diagnostic acumen and recognition of high-grade abnormality will vary according to the prevalence of high-grade abnormality in the clinic referral population. Other aspects of colposcopic evaluation are independent of case characteristics – for example, TZ type, adequacy of examination, hormonal status, and infection state.

Every colposcopy should assess the degree of abnormality as reflected in a simple scoring system, for example the Swede score (Strander et al., 2005) (see Annex 4). Sometimes it will be appropriate to take a biopsy, and sometimes not. Sometimes it will be appropriate to treat at the first/assessment visit, and sometimes not. Sometimes it will be appropriate to take a sample for cytology, for HPV testing, for endocervical brush cytology, or for other biomarkers of cervical cancer progression. If the TZ is not fully visible, the examination will be incomplete. In that case, the decision about management will depend on other case characteristics and whether to excise the TZ by way of a type 2 or type 3 excision. These

**Fig. 1.12.** (a) Colposcopic image of a normal transformation zone (TZ). (b) Colposcopic image of a TZ exhibiting low-grade changes. (c) Histological section of a normal squamocolumnar junction (40× magnification).



characteristics include:

- the patient's age and fertility aspirations;
- the reliability of the referral smear or other screening test;
- the risk of default from follow-up;
- the grade of suspected abnormality; and
- the availability of ancillary investigations (e.g. endocervical brush cytology, HPV testing, other biomarker tests).

Discovering high-grade abnormality when the smear reports a low-grade or borderline abnormality is more difficult, and it will often be prudent to take one or even two biopsies, but in a quality-assured colposcopy service the negative predictive value of a negative/normal colposcopic examination is very high, even without a colposcopically directed biopsy.

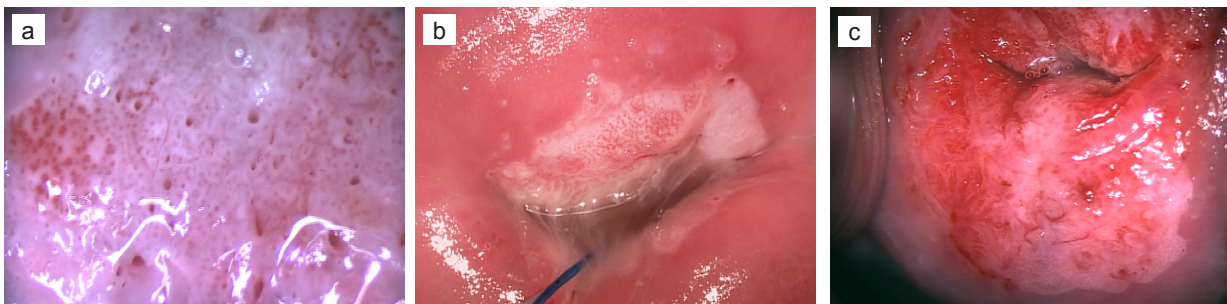
### 1.6.3 Diagnostic performance of colposcopy

The diagnostic accuracy of colposcopic examination, like that of any subjective test, will vary according to the training and expertise of the colposcopist as well as the prevalence of the disease. Also, it is influenced by knowledge of the referral screening test report. Finally, it performs better at the extremes of abnormality: normal/low-grade (Fig. 1.12) and definite high-grade (Fig. 1.13). The weakest diagnostic performance is with the middle or equivocal grade of abnormality. This is also true for cytology and pathology. The subjective error inherent in colposcopic assessment is very similar to the range of disparity that exists among cytologists and pathologists when assessing middle-grade

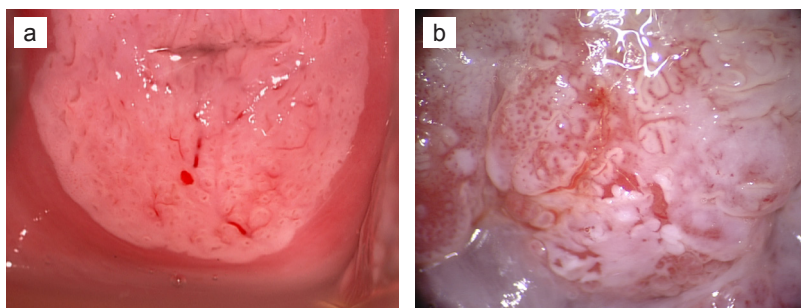
or equivocal abnormalities. There is no gold standard. A systematic and adequate colposcopic examination by a properly trained colposcopist will nearly always recognize HSIL when cytology has heralded it and the report is known (Fig. 1.13). It will sometimes recognize microinvasive disease (Fig. 1.14), but not always (Howe and Vincenti, 1991). This is not an issue if the TZ has been excised in its entirety.

When the cytology report suggests a low-grade or borderline abnormality and an adequate colposcopic examination by a trained colposcopist reveals low-grade or normal appearance (Fig. 1.12), the risk of HSIL occurring in the next 4 years or more is very low. In this situation, the negative predictive value of a quality-assured colposcopic examination, even with a positive

**Fig. 1.13.** (a) Colposcopic image of high-grade cervical intraepithelial neoplasia (CIN); coarse punctation. (b) Low-power colposcopic image of high-grade CIN; coarse mosaic pattern. (c) Low-power colposcopic image of high-grade CIN; note the atypical vessels and sharp margin at the 5 o'clock position.



**Fig. 1.14.** (a) Microinvasive squamous carcinoma. (b) Colposcopic image of microinvasive disease.



HPV test, is very high (Cruickshank et al., 2015; Kelly et al., 2012; Ricci et al., 2015). Completely normal cervical epithelium in a fully visible TZ is, again, usually very clear. Lesser grades of CIN are more difficult to discriminate from normal epithelium, but low-grade disease carries an exceedingly low risk of progressing to cancer.

Colposcopically directed biopsies are sometimes necessary and sometimes not. For most women, a colposcopic impression of CIN3 in the presence of a high-grade smear warrants excision of the TZ rather than a directed biopsy. Indeed, when a quality-assured laboratory reports a smear as CIN3, colposcopy will reveal a high-grade lesion in the great majority of cases. In this situation, when colposcopy does not find evidence of CIN3 the colposcopist should consider a colposcopically directed biopsy and, even more importantly, consultation with the referring laboratory and review of the referral smear, before deciding management. It is far better to competently perform a colposcopy than to rely on random biopsies. When an adequate colposcopic examination is normal, a random biopsy will very rarely find high-grade CIN (Song et al., 2015; Wentzensen et al., 2015). These comments, of course, pertain to the colposcopic examination that is adequate and is not compromised

by infection, previous treatment, or atrophy.

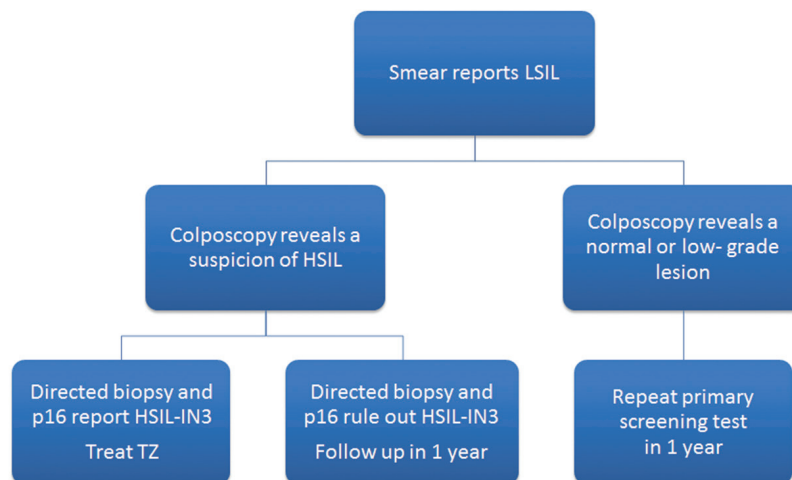
It is possible to miss a high-grade lesion when performing colposcopy, particularly if the lesion is small and possibly transient or when the colposcopic examination is compromised by inflammation, bleeding, or hormonal changes (atrophy or pregnancy) such that the examination should be recognized as being inadequate. Other reasons why colposcopy might underperform at a diagnostic level are that the colposcopist is inadequately trained or that the women being examined are an

unscreened population or women referred because of a screening test with low specificity.

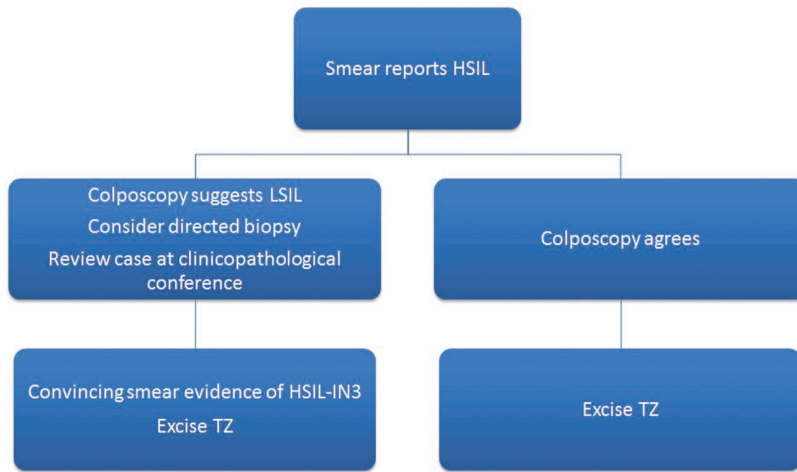
In deciding whether to take a biopsy, the colposcopist should consider whether the biopsy will alter management. At each end of the spectrum of suspected abnormality, a biopsy will not usually affect management. It is where uncertainty prevails that a colposcopically directed biopsy is valuable. Figs. 1.15 and 1.16 illustrate simplified approaches to managing suspected low-grade and high-grade lesions, respectively, in the context of a cytologically screened population.

Attempts to improve colposcopic diagnostic accuracy vary in their approach. One way is to improve colposcopic quality control. The Italian region of Emilia-Romagna has introduced a voluntary quality assurance system. The programme recently reported an Internet-based quality assurance programme. Of 65 colposcopists in the region, 59 participated in a review of 50 selected colpo-photographs and classified them according to colposcopic visibility of

**Fig. 1.15.** Algorithm of management where smear report is low-grade squamous intraepithelial lesion (LSIL)/atypical squamous cells of undetermined significance (ASCUS), given an adequate colposcopic examination in a type 1 transformation zone (TZ) by a properly trained colposcopist and with a cytology report from a quality-assured laboratory.



**Fig. 1.16.** Algorithm of management where smear report is high-grade squamous intraepithelial lesion (HSIL), given an adequate colposcopic examination in a type 1 transformation zone (TZ) by a properly trained colposcopist and with a cytology report from a quality-assured laboratory.



the squamocolumnar junction (i.e. TZ type), degree of abnormality, and need for biopsy. In that study, a biopsy was advised in 99% of women who ultimately had histologically proven CIN3. The authors (Bucchi et al., 2013) acknowledged that assessment of still images is not as good as video or in vivo assessment, but the colposcopists in that programme performed exceptionally well.

Another approach has been to advocate multiple random biopsies (Pretorius et al., 2004). The Chinese group that originally reported the advantage of random biopsy at colposcopy has recently reviewed its database (Song et al., 2015) and concluded that “random biopsy is not effective in the negative quadrant in women with positive colposcopy”. Wentzensen and colleagues (Wentzensen et al., 2015) have come to a similar conclusion.

## Key points

- Colposcopy is an assessment and diagnostic tool and offers the best way to manage women with suspected cervical precancer.
- A colposcopic examination should be systematic and structured and should always record the adequacy of the examination, the transformation zone type and size, and the degree of abnormality as reflected in an objective diagnostic scoring system, for example the Swede score.
- When quality-assured, colposcopic examination has a high negative predictive value.
- Excisional therapy for cervical precancer should always be performed under colposcopic vision.